



RESEARCH ARTICLE

Preliminary Studies on Antihyperglycemic Effect of Aqueous Slurry of *Averrhoa carambola* L. Fruits in Streptozotocin Induced Diabetic Rats

Patil AG^{1*}, Koli SP¹, Patil DA², Narayane VS³, Phatak AV³

¹Department of Botany-Herbal Sciences, Birla College, Kalyan - 421 304, (M.S.), India.

²Department of Botany, Smt. C.H.M. College, Ulhasnagar - 3, (M.S.), India.

³Department of Zoology, Birla College, Kalyan - 421 304, (M.S.), India.

Manuscript No: IJPRS/V3/I1/00132, Received On: 15/03/2014, Accepted On: 20/03/2014

ABSTRACT

Medicinal plants play an important role in the management of Diabetes Mellitus (DM) especially in developing countries where resources are meager. *Averrhoa carambola* L. (Family: Oxalidaceae), which is popularly known as the “Star fruit” or “Kamrakh”, has various medicinal uses viz. antipruritic, antipyretic, anthelmintic, anti-inflammatory, anti-ulcer, antimicrobial etc.. Fruits of *A. carambola* L. are a very good source of natural antioxidants due to presence of L-ascorbic acid, (-) Epicatechin and gallic acid and are also very rich in dietary fibers, especially insoluble fibers. The present study was carried out to evaluate antihyperglycemic effect of *Averrhoa carambola* L. fruits in normal and streptozotocin induced diabetic rats. The oral feeding of aqueous slurry of the fruit powder in diabetic rats for 21 days at a dosage of 1000 mg/kg body weight, exhibited a significant ($P < 0.05$) reduction in fasting blood glucose level. Histopathology studies of three vital organs viz. pancreas, liver and kidney showed good recovery when compared to the diabetic control groups. Based on these results, it is evident that *A. carambola* L. fruits have antihyperglycemic effect and must be considered as a potential candidate for future studies on Diabetes Mellitus (DM).

KEYWORDS

Averrhoa Carambola L. fruit, Antihyperglycaemic, Streptozotocin

INTRODUCTION

Diabetes Mellitus (DM) affects approximately 150 million people around the world. It is estimated that by 2025 this number would be doubled, with a prevalence that varies markedly from population to population¹. Statistical projections about India suggest that the number of diabetes will rise from 15 million in 1995 to 57 million in the year 2025 making it the country with the highest number of diabetic people in the world^{2,3}. Diabetes Mellitus is characterized by group of metabolic disorders.

Deficiency or insensitivity of insulin causes glucose to accumulate in the blood, leading to various complications. Clinically diabetic patients are characterized by marked increase in blood glucose level followed by mild hyperlipidemia. Effective treatment includes controlling hyperglycemia as well as secondary complications⁴. In Ayurveda various herbs are reported for treating and preventing diabetes. Herbal drugs have lesser or no side effects and are less expensive as compared to synthetic drugs. Therefore, identification of antihyperglycemic leads from the plants has become more important⁴. *Averrhoa carambola* L. commonly known as Star fruit or kamrakh

***Address for Correspondence:**

A. G. Patil

Department of Botany-Herbal Sciences,
Birla College, Kalyan - 421 304, (M.S.), India.

E-Mail Id: dravinashpatil@rediffmail.com

belongs to Family Oxalidaceae. The leaves of *A. carambola* L. are antipruritic, antipyretic, anthelmintic and are also useful in scabies, fractured bones and various types of poisoning, intermittent fevers and intestinal worms. The leaves have been eaten as a substitute for sorrel⁵. In Brazil, the leaves are recommended to treat diabetes⁶. Treatment with hydroalcoholic extracts of the leaves resulted in reduction in fasting glycemia, which was not mediated by an inhibition of hepatic gluconeogenesis and / or an increased glucose uptake by muscles⁷.

In India, the ripe carambola fruit or its juice is occasionally used to counteract fever. A salve made of the fruit is employed to relieve eye afflictions. In Brazil, the carambola is recommended as diuretic in kidney and bladder complaints. In Chinese Materia Medica it is used to quench thirst, increase the salivary secretion and in fever⁵.

The fruits are useful in diarrhoea, vomiting, hyperdipsea, haemorrhoids, intermittent fever, hepatodynia, scabies and various kinds of poisoning and general debility. The fruit is sour, astringent to the bowels, allays thirst and is very useful for the treatment of intestinal worms⁸. The ripe fruit is a good remedy for bleeding piles, particularly for internal piles. It is also useful in relieving thirst and febrile excitement. The dried fruit is given in fevers; it is cooling and possesses antiscorbutic properties. It is considered as one of the best Indian cooling medicines⁵. The fruits are found to possess a high level of insoluble dietary fibre, alcohol insoluble solid and water insoluble solid. These fiber rich fractions might help to control post prandial serum glucose⁹. Various research reports have established that dietary fibre can provide health promoting effects such as reduced risk of cardiovascular disease. It is reported that carambola is rich in dietary fibre as especially insoluble fibre and contains a high concentration of water insoluble fibre rich fraction, which can be used as a promising cholesterol lowering ingredient in human diets or new formulations of fibre – rich functional foods⁹. It is claimed eating the fruit reduces blood sugar level in diabetes¹⁰.

With this background, the present study aims to evaluate the antihyperglycaemic potential of aqueous slurry of *Averrhoa carambola* L. fruits in normal and streptozotocin-induced diabetic rats.

MATERIALS AND METHOD

Plant Material

The fruits of *Averrhoa carambola* L. were collected from Badlapur and Karjat (Maharashtra). The herbarium of *Averrhoa carambola* L. plant was prepared and authenticated from Blatter Herbarium, St. Xavier's College, Mumbai.

Drying

The fruits collected were washed under running tap water and were blotted dry. The fruits were then cut into small pieces and kept for drying in oven at temperature $40 \pm 2^\circ$ C for five days. The dried fruits were ground into powder and passed through sieve No. 100 and used for further experimental purpose.

Preparation of Aqueous Slurry

The aqueous slurry of *A. carambola* fruit powder (ASAC) was prepared in water and used for the dosing purpose (1000 mg powder/kg body weight/ day).

Phytochemical Screening

Preliminary phytochemical analysis of *Averrhoa carambola* L. fruit using various solvents namely water, methanol, ethanol, benzene and petroleum ether was carried out. The extracts were prepared by soaking 1 g of fruit powder in 10 ml of respective solvent, vortexed, kept overnight for extraction at room temperature and then filtered. The filtrate was used for the preliminary phytochemical analysis. The tests were performed according to methods described by Khandelwal (2008)¹¹ and Kokate (2008)¹². TLC for various phytoconstituents was carried out as methods described by Wagner and Bladt (1996)¹³.

Acute Toxicity Studies

Albino Wistar rats, 8-12 weeks old, weighing in range of 120-180 g, were procured from

Haffkine Institute, Parel. The animals were accommodated in groups of five in polypropylene cages with stainless steel grill top and a bedding of clean paddy husk was provided. The animals were maintained in air conditioned room with controlled temperature maintained in the range of 22 - 25° C and alternating 12 hour periods of light and dark cycle. The relative humidity was close to 60 %. The animals were acclimatized to standard laboratory conditions prior to experimentation. The guidelines issued by Institutional Animal Ethics Committee of Ramnarain Ruia College, Mumbai, India with CPC SEA registration no. CPC SEA/315, regarding the maintenance and dissection of small animals were strictly followed. Rats were administered a dose of 2000mg/kg body weight/day for 14 days and were then examined for any signs of behavioural changes and mortality.

Efficacy Study

All experiments were performed on female Albino Wistar rats (200– 250 g) obtained from the Haffkine Institute, Parel, Mumbai, Maharashtra. The animals were accommodated in groups of six in polypropylene cages with stainless steel grill top and a bedding of clean paddy husk. Animals were maintained under a constant 12-h light and dark cycle and an ambient temperature of 22–25°C. The animals were acclimatized for 2 weeks before being used for the experiments. The guidelines issued by Institutional Animal Ethics Committee of Ramnarain Ruia College, Matunga, Mumbai, India with CPC SEA registration no. CPC SEA/315, regarding the maintenance and dissection of small animals were strictly followed. The animals were fed on the standard pellet diet (Amrut Feed, Pune) and water was given *ad libitum*.

Induction of Experimental Diabetes Mellitus

The overnight fasting rats were made diabetic with streptozotocin (STZ) (Sigma, St Louis, MO; 60 mg/kg, intraperitoneally). The STZ was prepared freshly by dissolving it in Na-citrate buffer (0.01 M, pH 4.5) and maintained on ice prior to use; the injection volume was 0.2 ml.

Diabetes was confirmed in the rats by measuring the fasting blood glucose concentration after 72 h of STZ administration. The rats with glucose level above 300 mg/dl were considered to be diabetic and were used in the experiment. Animals had free access to food and water after the STZ injection.

Experimental Design

The hyperglycemic rats were divided on day zero into four groups (each with 6 rats). The fasting serum glucose level concentrations were measured on day zero. Group I and Group II served as normal control and diabetic control, treated orally with distilled water respectively. Group III and Group IV diabetic rats were orally treated with glibenclamide (500 µg/kg body weight) and ASAC (1000 mg/ kg body weight) respectively for 3 weeks. Body weight, food and water intake were monitored daily for 3 weeks.

Sample Collection

To detect blood glucose level on 0, 7th and 14th day, blood was withdrawn retro-orbitally from the inner canthus of the eye with the help of heparinized capillary tube. On day 21, after 16 h fasting, the rats were sacrificed by cervical dislocation and the blood was collected for estimation of the serum glucose. Blood samples were collected in Eppendroff tubes and allowed to clot for ten minutes. Serum was separated by centrifuging at 3000 rpm for 10 mins. and analyzed further.

Biochemical Analysis

Blood glucose was estimated using Crest Biosystems kit (Enzymatic glucose oxidase peroxidase (GOD-POD) method by Trinder, (1969)¹⁴.

Histopathological Studies

After collecting the blood for the biochemical analysis, the animals were sacrificed, and small piece of pancreas, liver and kidney were taken and fixed in 10% buffered formalin, embedded in paraffin wax, serial sections of 5 micrometer were cut, stained with hematoxylin-eosin, mounted on glass slides and

photomicrographed. The observations made were recorded.

Statistical Analysis

Values are expressed as the mean \pm SE for six animals in each group. Statistical analysis was done by using One-way ANOVA followed by Dunnett's multiple comparison tests at 5% level of significance.

RESULTS

Preliminary phytochemical analysis of *Averrhoa carambola* L. fruit extracts showed presence of aleurone grains, amino acids, proteins, carbohydrates, starch, fats and fixed oils, glycosides, mucilage, tannins, steroids, phenols, flavonoids, saponins, essential oils, and resins.

Phytochemical analysis by HPTLC of *Averrhoa carambola* L. fruit extracts showed presence of anthracene, bitter principles, cardiac glycosides, coumarins, essential oils, lignans, pungent – tasting principles, saponins, triterpenes and valepotraites.

No toxic effect was observed on treatment up to 2000 mg/kg body weight of ASAC as the behavior of the treated rats appeared normal and no death occurred. The ASAC was found safe till the dose of 2000 mg/kg body weight in rats.

Levels of serum glucose were studied in normal control, diabetic control, modern drug control (glibenclamide) and rats treated with ASAC (Table No. 1, Fig. 1).

The serum glucose level of diabetic control group showed increase from day zero to twenty first days, whereas the group treated with modern drug showed decrease in the serum glucose level. In the group treated with ASAC showed significant decrease in serum glucose level after 21 days of treatment. These readings are at par with levels of glucose for modern drug treated group ($P < 0.05$).

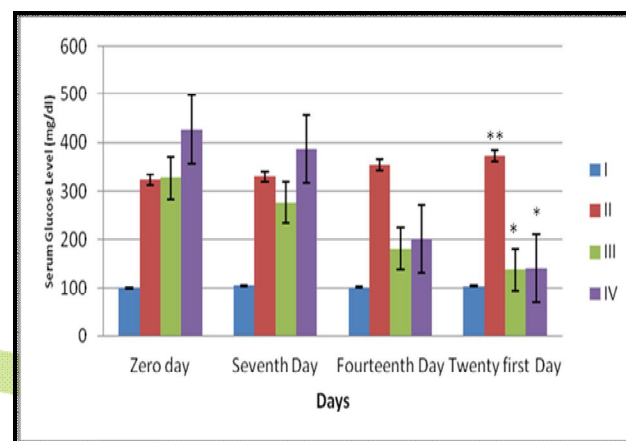


Figure 1: Effect of aqueous slurry of *Averrhoa carambola* L. fruit powder on Serum Glucose Level (mg/dl)

Histopathology

Transverse section of pancreas of normal control rat showed dense islet of langerhans (IL), which are prominently found amidst the pancreatic accini (PA). Some of the cells of the islet possessed light nuclei (LN), while most other had darkly stained nuclei (DN).

Table No. 1: Effect of aqueous slurry of *Averrhoa carambola* L. fruit powder on Serum Glucose Level (mg/dl)

Groups	Zero day	Seventh Day	Fourteenth Day	Twenty first Day
I	101.10 \pm 1.33	106.07 \pm 1.46	102.47 \pm 1.99	104.88 \pm 1.66
II	323 \pm 4.25	330.83 \pm 4.71	355.17 \pm 6.94	372.67 \pm 6.42**
III	327 \pm 3.85	275.67 \pm 5.08	181.67 \pm 8.11	137.33 \pm 6.32*
IV	427.5 \pm 4.78	387 \pm 4.95	201.9 \pm 1.35	139.7 \pm 2.43*

Each value is mean \pm SEM. for 6 rats in each group;

*:- Shows significant decrease at $P < 0.05$ compared to diabetic control

**:- Shows significant increase at $P < 0.05$ compared to normal control

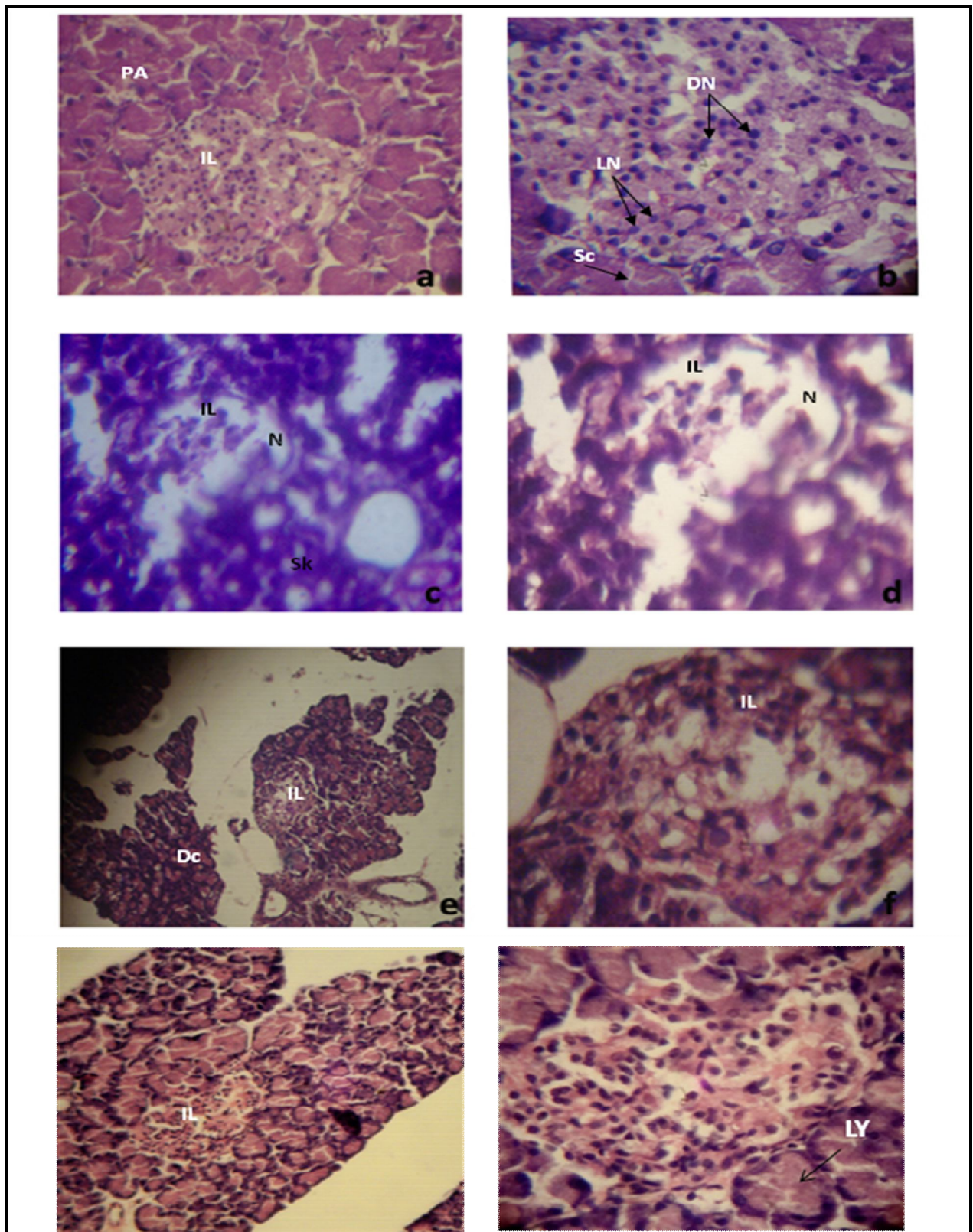


Plate 1: Pancreas - Normal control (a - 10x, b - 40x); Diabetic control (c - 10x, d - 40x); Modern drug control (e - 10x, f - 40x); ASAC (g - 10x, h - 40x)

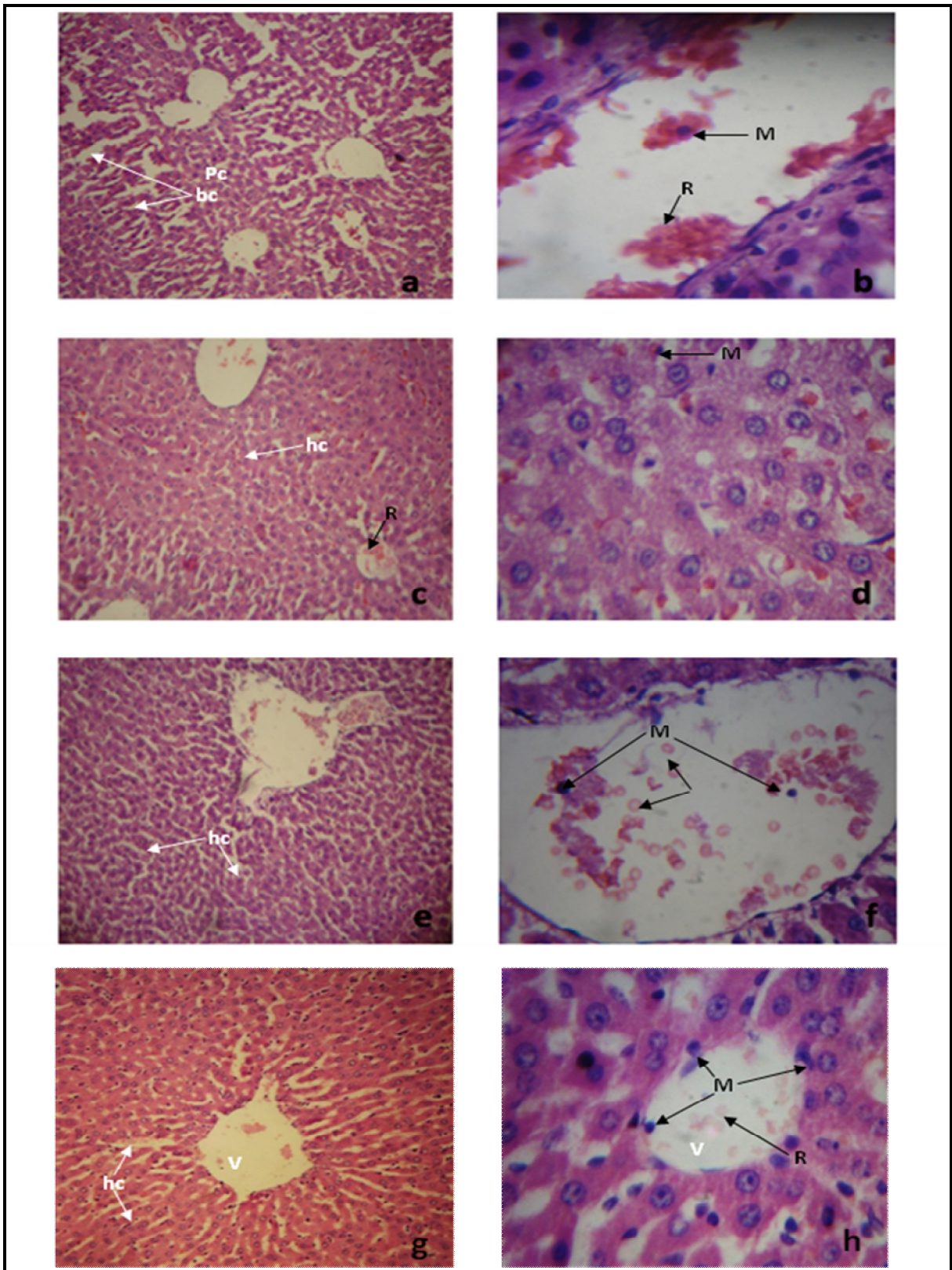


Plate No. 2: Liver - Normal control (a - 10x, b - 40x); Diabetic control (c - 10x, d - 40x); Modern drug control (e - 10x, f - 40x). ASAC (g - 10x, h - 40x).

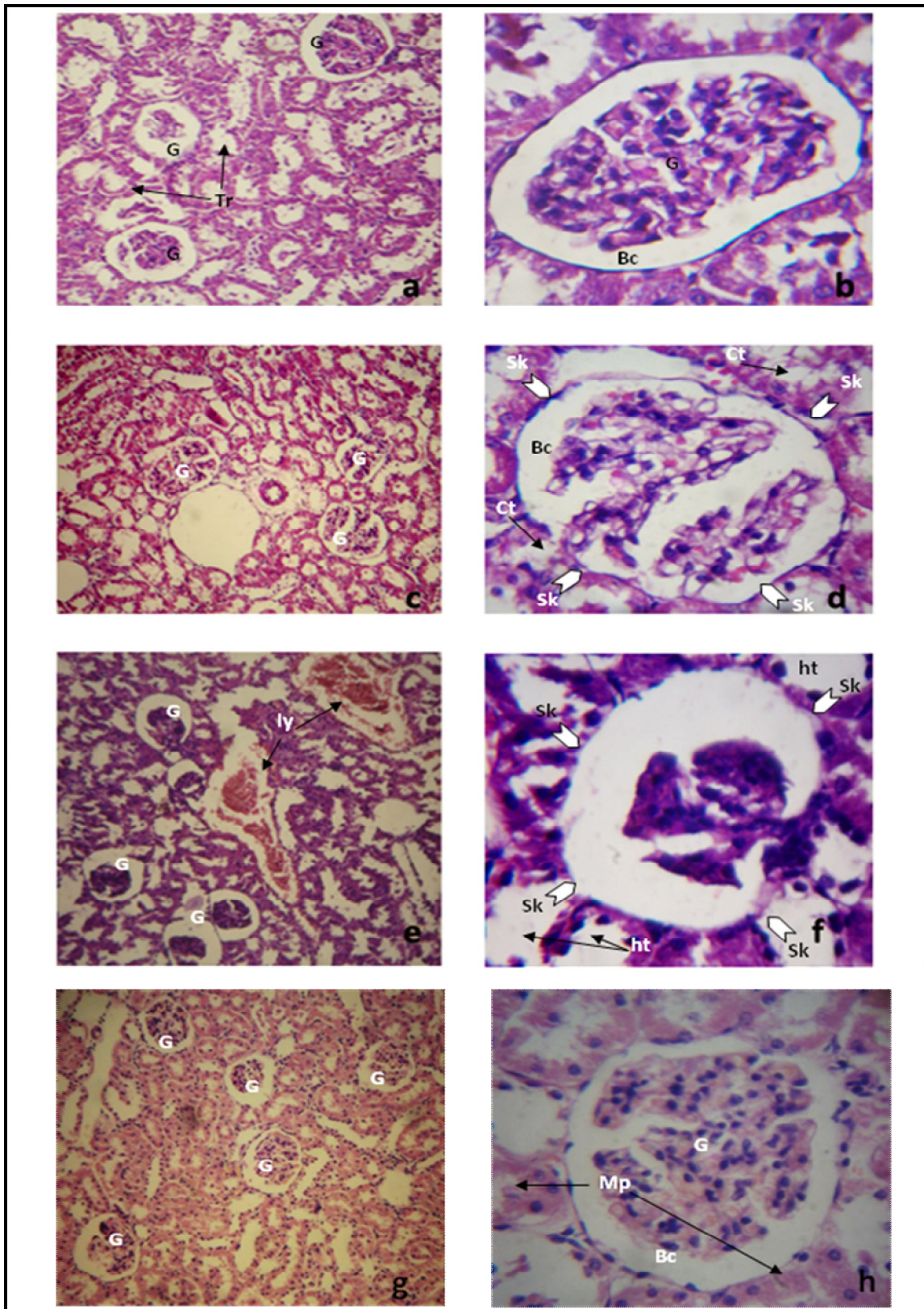


Plate No. 3: Kidney - Normal control (a - 10x, b - 40x); Diabetic control (c - 10x, d - 40x); Modern drug control (e - 10x, f - 40x). ASAC (g - 10x, h - 40x).

Accini presented normal structure with all of them having cells filled with their secretion (Sc) (Fig. 2a, 2b), whereas diabetic control rat tissue showed severe necrosis (N) caused due to the drug abuse. The accini as well as islets showed complete shrinkage (Sk) and loss of structural integrity (Fig. 2c, 2d). In modern drug treated group, the islet (IL) appeared slightly shrunken as compared to normal but much revived as compared to diabetic control. The accini appeared considerably destroyed and showed damaged cells (Dc) (Fig. 2e, 2f).

Transverse section of pancreas treated with ASAC diabetic rats showed that islet appeared almost revived as the islet occupied larger area than the modern drug control group and diabetic control group. The islet showed higher density of cells with darkly stained Nuclei (DN). Few lightly stained Nuclei (LN) were also visible in the islet. Accini although did not show complete recovery as many of them still appeared broken and lysed (ly) (Fig. 2g, 2h).

Transverse section of liver of normal control rats showed parenchyma cells (Pc) which appeared normal in their usual hepatic cords. Bile canaliculi (bc) appeared clear and empty, which suggested complete drain of bile. Hepatic portal vein showed presence of RBC's (R) and macrophages (M) (Fig. 3a, 3b), whereas T.S. of diabetic control group of rats showed that tissue has a typical appearance of hypertrophy as there is a considerable reduction in the space between hepatic cords (hc) and sinusoidal spaces. Macrophagic (M) activity is on increased side evident due to the presence of many macrophages nearly in all the venules. Some of the canaliculi showed presence of RBC's (R). There was no evidence of biliary obstruction (Fig. 3c, 3d).

Transverse section of liver of modern drug treated diabetic rats showed normal hepatic cords (hc) and hepatic cells. The sinusoidal spaces appeared moderately filled with amorphous material. No evidence of hypertrophy of bile canaliculi. Venules (V) showed RBC's and few macrophages (M) (Fig. 3e, 3f).

Transverse section of liver of ASAC treated diabetic rats showed healthy appearance with no evidence of hypertrophy. Hepatic cords and cells are normal in appearance. The canaliculi and portal venules are clear. Macrophages (M) were more in number compared to diabetic control group (Fig. 3g, 3h).

Histological studies of kidney in normal control groups after staining with hematoxylin-eosin showed normal appearance of malphigian body consisting of clear Bowman's capsule (Bc) and compact glomerulus (G). Few RBC's were found scattered in the glomerulus. Tubular regions (Tr) made up of PCT and DCT showed normal thickness of their epithelial lining, which appeared rather squamous in their form (Fig. 4a, 4b); whereas in diabetic control group glomerulus appeared shredded and shrunken (Sk). The Bowman's capsule (Bc) showed increased diameter compared to normal. Convolute tubules (Ct) appeared dilated and showed several breaks in its epithelium. Most of the tubules showed accumulation of amorphous material in their lumen which is probably mucopolysaccharide (Fig. 4c, 4d). The T.S. of kidney of diabetic rats treated with modern drug showed clear nephrons without any accumulation in lumen of PCT and DCT, although haemolysis (ly) was evident occasionally. Tubules appeared hypertrophied (ht), while glomerulus showed onset of necrosis (Fig. 4e, 4f).

The diabetic rats treated with the ASAC showed close resemblance to that of normal or untreated kidney. Glomerulus (G) appeared round and globular occupying nearly the entire inner space of Bowman's capsule (Bc). Some of the convolute tubules showed accumulation of amorphous, mucopolysaccharides (Mp); while most other tubules showed clear lumen which is an indication of partial recovery (Fig. 4g, 4h).

DISCUSSION

Though different types of oral hypoglycaemic agents are available along with insulin for the treatment of diabetes, there is an increased demand by patients to use the natural products with antidiabetic activity¹⁵. The present study

was designed to investigate antihyperglycemic potential and to provide scientific validation to prove antihyperglycemic activity of *Averrhoa carambola* L. fruit.

In the present investigation it was found that the phytochemical analysis of various solvent extracts of *A. carambola* fruits showed presence of glycosides, mucilage, tannins, steroids, phenols, flavonoids, saponins, triterpenes and bitter principles. These phytoconstituents were speculated to account for the observed pharmacological effects of the extract.

Oral administration of the flavonoids content (8%) of the seeds of *Cuminum nigrum* caused a significant blood glucose lowering (0.5 to 1.5 g/kg), both in normoglycemic and alloxan-induced diabetic rabbits¹⁶. Many flavonoids containing plants serve as a hidden wealth of potentially useful natural products for diabetes control¹⁷. A naturally occurring flavonoids (-)epicatechin (1)¹⁸, chard – *Beta vulgaris* L. var *carda*¹⁹, salyamarin²⁰, *Terminalia catappa* leaves²¹, walnut leaves – *Julgaris regia* L.²² and *Gymnema sylvestre*^{23,24} used as traditional diabetes managements exert their antidiabetic action by regeneration of previously necrosed pancreatic beta cells, hence re-establishing insulin production²⁵.

Sui *et al.* (1994)²⁶ reported that saponin isolated from the leaves of *Acanthopanax senticosus*, injected to mice (100, 200 mg/kg, i.p.) decreased experimental hyperglycemia. Abdel-Hassan *et al.* (2000)²⁷ suggested that the saponin glycosides components should be responsible for the hypoglycemic effect of the rind of *Citrillus colocynthis*. It seems that the hypoglycemic effect of *Aloe barbadensis* and its bitter principle may be mediated through stimulating synthesis and/or release of insulin from the beta-cells of the islets of Langerhans²⁸.

All the plants used for diabetic treatment are found to elaborate potent antioxidant principles such as phenolic or vitamin compounds²⁹. Fruits of *Averrhoa carambola* L. are very good source of natural antioxidants, it showed presence of L-ascorbic acid, (-) epicatechin and gallic acid in gallotannin forms³⁰. It also contains ascorbic

acid, oxalic acid, tartaric acid, citric acid, α -ketoglutarate, succinate and trace of fumaric acid³¹. Sequential extraction of *Medicago sativa* with solvents revealed insulin-releasing activity in both the methanol and water fractions indicating a cumulative effect of more than one constituent³².

Chau *et al.* (2004)⁹ reported that pomace of *Averrhoa carambola* L. was found to possess a high level of insoluble fiber-rich fractions (FRFs) including insoluble dietary fibers, alcohol-insoluble solid and water-insoluble solid (46.0-58.2 g/100 g of pomace). These FRFs were mainly composed of pectic substances and hemicelluloses. The oral administration of the pectin isolated from the fruit of the *Coccinia indica* at the dose of 200 mg/100 g BW/day produced a reduction in glycemia³³. Sindurani and Rajamohan (2000)³⁴ also reported beneficial effect of inclusion of coconut fibre in the diet. Intake of crude dietary fiber initially resulted in an increase in blood glucose and later a decrease when compared to control³⁵.

The 21 days' study of aqueous slurry of *Averrhoa carambola* fruit (1000 mg/kg) significantly decreased serum blood glucose level in STZ induced diabetic rats compared to diabetic control rats. These readings are at par with levels of glucose for modern drug (Glibenclamide) treated group ($P < 0.05$). This antihyperglycemic effect may have resulted from the potentiation of insulin from existing β -cells of the islets of Langerhans³⁶. Administration of ASAC showed expansion of pancreatic islet cells and Glibenclamide treatment showed normal islet cells supporting the biochemical analysis³⁷. Saxena *et al.* (1993)³⁸ concluded that SW1 isolated from *Swertia chirayita* lowers glycemia by stimulating insulin release from the islets of Langerhans.

Glibenclamide-used as the reference antidiabetic drug in this study is a member of sulphonylureas. It has been proposed that sulphonylureas produce their hypoglycemic effect primarily through increased release of insulin from pancreatic β -cells³⁹. Thus, any

plant secondary metabolite or chemical constituent which is capable of affecting the insulin secretion from pancreatic β -cells will be a good mimicker of sulphonylureas. Due to least or no side-effects of plant based drugs, these can be better candidates for the treatment of diabetes mellitus because synthetic drugs are known to have undesirable side-effects⁴⁰.

Histopathological studies have shown that the diabetogenic action of STZ is due to specific cytotoxicity actions against hepatocytes and pancreatic β -cells. The 21 days' treatment of ASAC results in partial decrease of degenerative cells and the protective effect of liver and pancreas against STZ action in diabetic rats. In the pancreatic sections of diabetic rats fed with *A. carambola* L., the islets were comparable to normal rats and transverse section of liver showed healthy tissue with no evidence of hypertrophy. The diabetic rats treated with the *Averrhoa carambola* L. aqueous slurry showed close resemblance to that of normal or untreated kidney. Some of the convoluted tubules showed accumulation of amorphous, mucopolysaccharides (Mp); while most other tubules showed clear lumen which is an indication of partial recovery.

From the present study, it can be concluded that aqueous slurry of *A. carambola* L. fruit powder and some of its phytoconstituents possess significant antihyperglycemic property. Further studies are needed to investigate and elucidate the possible mechanism of action of active ingredients, establish complete safety profiles and evaluate the potential of *Averrhoa carambola* L. powder and its active constituents for the management of diabetes and associated complications in the clinical trials.

ACKNOWLEDGEMENT

Authors are thankful to UGC, New Delhi for sanctioning Major Research Project and Mr. Kishore Desai of Sanjay Pathology Laboratory for facilitating Biochemical analysis.

REFERENCES

1. O'Rahilly, S., Barroso, I., & Wareham, N. J. (2005). Genetic factors in type 2 diabetes: the end of the beginning?. *Science*, 307(5708), 370-373.
2. King, H., Aubert, R. E., & Herman, W. H. (1998). Global burden of diabetes, 1995–2025: prevalence, numerical estimates, and projections. *Diabetes care*, 21(9), 1414-1431.
3. Boyle, J. P., Honeycutt, A. A., Narayan, K. V., Hoerger, T. J., Geiss, L. S., Chen, H., & Thompson, T. J. (2001). Projection of Diabetes Burden Through 2050 Impact of changing demography and disease prevalence in the US. *Diabetes care*, 24(11), 1936-1940.
4. Srivastava, A. K., & Maurya, R. (2010). Antihyperglycemic activity of compounds isolated from Indian medicinal plants. *Indian Journal of Experimental biology*, 48, 294-298.
5. Kirtikar, K. R., & Basu, B. D. (1984). *Indian Medicinal Plants*, Vol. 1, 2nd Edition, Published by Lalit Mohan Basu.
6. Martha, R. C. D., Poubel, J., Ferreira, L. C. L., Lima, R. S., Borrás, M. R., Costa, P. R. C., & Roland, I. A. (2000). Atividade hipoglicêmica de *Averrhoa carambola* L. usada em Manaus como antidiabético. *NewsLab*, 38, 142-148.
7. Ferreira, E. B., Fernandes, L. C., Galende, S. B., Cortez, D. A., & Bazotte, R. B. (2008). Hypoglycemic effect of the hydroalcoholic extract of leaves of *Averrhoa carambola* L. (Oxalidaceae). *Revista Brasileira de Farmacognosia*, 18(3), 339-343.
8. Sheth, A. (2005). *The Herbs of Ayurveda*, Published by Ashok K. Sheth, Vol 1 p. 140.
9. Chau, C. F., Chen, C. H., & Lee, M. H. (2004). Characterization and physicochemical properties of some potential fibres derived from *Averrhoa carambola*. *Food/Nahrung*, 48(1), 43-46.
10. Solomon, C. (1998). *Charmaine Solomon's Encyclopedia of Asian Food*. Boston: Periplus Editions.

11. Khandelwal, K. R. (2008). Practical Pharmacognosy Techniques and Experiments. Nirali Prakashan. Pune, India.
12. Kokate, C. K., Purohit, A. P., & Gokhale, S. B. (2008). Pharmacognosy. Nirali Prakashan, Pune, 593-597.
13. Wagner, H. (1996). *Plant drug analysis: a thin layer chromatography atlas*. Springer.
14. Trinder, P. (1996). Determination of glucose in serum, plasma and CSF. GOD/POD method. *Ann Clin Biochem*, 6, 24-27.
15. Venkatesh, S., Reddy, G. D., Reddy, B. M., Ramesh, M., & Rao, A. V. N. (2003). Antihyperglycemic activity of *Caralluma attenuata*. *Fitoterapia*, 74(3), 274-279.
16. Ahmad, M., Akhtar, M. S., Malik, T., & Gilani, A. H. (2000). Hypoglycaemic action of the flavonoid fraction of *Cuminum nigrum* seeds. *Phytotherapy research*, 14(2), 103-106.
17. Cazarolli, L. H., Zanatta, L., Alberton, E. H., Reis Bonorino Figueiredo, M. S., Folador, P., Damazio, R. G., ... & Mena Barreto Silva, F. R. (2008). Flavonoids: cellular and molecular mechanism of action in glucose homeostasis. *Mini reviews in medicinal chemistry*, 8(10), 1032-1038.
18. Chakravarthy, B. K., Gupta, S., & Gode, K. D. (1982). Functional beta cell regeneration in the islets of pancreas in alloxan induced diabetic rats by (-)-epicatechin. *Life Sciences*, 31(24), 2693-2697.
19. Bolkent, R., Yanarda, O., & Tabakolu-Ouz, Ozsoy-Sacan. (2000). Effect of Chard (*Beta vulgaris* L. Var. Cida) extract on pancreatic B cells in Streptozotocin-Diabetic Rats: a Morphological and Biochemical Study. *Journal of Ethnopharmacology*, 73(1-2), 251-259.
20. Soto, C., Mena, R., Luna, J., Cerbon, M., Larrieta, E., Vital, P., & Lara, A. (2004). Silymarin induces recovery of pancreatic function after alloxan damage in rats. *Life sciences*, 75(18), 2167-2180.
21. Ahmed, S. M., Swamy BM, V., Gopkumar, P., Dhanapal, R., & Chandrashekara, V. M. (2005). Anti-diabetic activity of *Terminalia catappa* Linn. leaf extracts in alloxan-induced diabetic rats. 4(1), 38-39.
22. Jelodar, G., Mohsen, M., & Shahram, S. (2008). Effect of walnut leaf, coriander and pomegranate on blood glucose and histopathology of pancreas of alloxan induced diabetic rats. *African Journal of Traditional, Complementary and Alternative Medicines*, 4(3), 299-305.
23. Yeh, G. Y., Eisenberg, D. M., Kaptchuk, T. J., & Phillips, R. S. (2003). Systematic review of herbs and dietary supplements for glycemic control in diabetes. *Diabetes care*, 26(4), 1277-1294.
24. Bnouham, M., Ziyat, A., Mekhfi, H., Tahri, A., & Legssyer, A. (2006). Medicinal plants with potential antidiabetic activity-A review of ten years of herbal medicine research (1990-2000). *International Journal of Diabetes and Metabolism*, 14(1), 1-25.
25. Atangwho, I. J., Ebong, P. E., Egbung, G. E., Akpaso, M. I., & Asuquo, E. E. (2010). Histological Effect of Combined Extracts of *Veronica Amygdalina* and *Azadirachta Indica* on Normal and Diabetic Rats: the Pancreas and Liver. *Research Journal of Agriculture and Biological Sciences*, 6(4), 514-521.
26. Sui, D. Y., Lu, Z. Z., Li, S. H., & Cai, Y. (1994). [Hypoglycemic effect of saponin isolated from leaves of *Acanthopanax senticosus* (Rupr. et Maxim.) Harms]. *Zhongguo Zhong yao za zhi= Zhongguo zhongyao zazhi= China journal of Chinese materia medica*, 19(11), 683-5.
27. Abdel-Hassan, I. A., Abdel-Barry, J. A., & Tariq Mohammeda, S. (2000). The hypoglycaemic and antihyperglycaemic effect of *Citrullus colocynthis* fruit aqueous extract in normal and alloxan diabetic rabbits. *Journal of Ethnopharmacology*, 71(1), 325-330.

28. Ajabnoor, M. A. (1990). Effect of aloes on blood glucose levels in normal and alloxan diabetic mice. *Journal of ethnopharmacology*, 28(2), 215-220.
29. Jayakumar, G., Ajithabai, M. D., Sreedevi, S., Viswanathan, P. K., & Remeshkumar, B. (2010). Ethnobotanical survey of the plants used in the treatment of diabetes. *Indian Journal of Traditional Knowledge*, 9(1), 100-104.
30. Shui, G., & Leong, L. P. (2004). Analysis of polyphenolic antioxidants in star fruit using liquid chromatography and mass spectrometry. *Journal of chromatography A*, 1022(1), 67-75.
31. Morton, J. F. (1987). *Fruits of warm climates*. JF Morton. 125-128.
32. Gray, A. M., & Flatt, P. R. (1997). Pancreatic and extra-pancreatic effects of the traditional anti-diabetic plant, *Medicago sativa* (lucerne). *British Journal of Nutrition*, 78(02), 325-334.
33. Kumar, G. P., Sudheesh, S., & Vijayalakshmi, N. R. (1993). Hypoglycemic effect of *Coccinia indica*: mechanism of action. *Planta Med*, 59(4), 330-332.
34. Sindurani, J. A., & Rajamohan, T. (2000). Effects of different levels of coconut fiber on blood glucose, serum insulin and minerals in rats. *Indian journal of physiology and pharmacology*, 44(1), 97-100.
35. Diaz, J., Durruty, P., Tapia, J. C., Carrasco, E., Riesco, V., Durruty, G., Garcia-de-los-Rios, M. (1990). The effect of dietary fiber (White lupine brain) in the treatment of non-insulin-dependent diabetes, *Rev. Med. Chil.*, 118, 24-32.
36. Satyaprakash, R. J., Rajesh, M. S., Bhanumathy, M., Harish, M. S., Shivananda, T. N., Shivaprasad, H. N., & Sushma, G. (2014). Hypoglycemic and Antihyperglycemic effect of *Ceiba pentandra* L. Gaertn in Normal and Streptozotocin-induced Diabetic Rats. *Ghana medical journal*, 47(3), 121-127.
37. Gupta, R., Sharma, A. K., Dobhal, M. P., Sharma, M. C., & Gupta, R. S. (2011). Antidiabetic and antioxidant potential of β -sitosterol in streptozotocin-induced experimental hyperglycemia. *Journal of diabetes*, 3(1), 29-37.
38. Saxena, A. M., Bajpai, M. B., Murthy, P. S., & Mukherjee, S. K. (1993). Mechanism of blood sugar lowering by a Swerchrin-containing hexane fraction (SWI) *Swertia chirayita*. *Indian J Exp Biol*, 31, 178-181.
39. Jackson, J. E., & Bressler, R. (1981). Clinical pharmacology of sulphonylurea hypoglycaemic agents. Part I, *Drugs*, 22, 211.
40. Del Prato, S., & Pulizzi, N. (2006). The place of sulfonylureas in the therapy for type 2 diabetes mellitus. *Metabolism*, 55, S20-S27.