



CASE STUDY

Role of Kshar Pratisaran in Internal Haemorrhoids: A Case Study

Anju Lata*

Lecturer, Shalya Dept. Shri Dhanwantry Ayurvedic College and Hospital, Chandigarh, India.

Manuscript No: IJPRS/V6/I4/00074, Received On: 25/10/2017, Accepted On: 03/12/2017

ABSTRACT

A male patient of 48 years attended shalya opd with the complaints of bleeding per anum on defecation. On anorectal examination it was provisional diagnosed as the case of internal haemorrhoids. Apamarg kshar pratisaran done in that condition after performing required clinical examination and investigation. Finally patient was successfully treated with this parasurgical approach without any complication. So the result of kshar karma in internal haemorrhoids was found quite satisfactory in the present case. In order to establish this fact further study for longer duration and on larger sample is required.

KEYWORDS

Internal Haemorrhoids, Kshar Karma, Parasurgical

INTRODUCTION

Definition of swasthpusura given by sushruta that one is known to be healthy when dosha, agni, dhatu and mala are in state of equilibrium in structure and function along with happy mind.¹

Kshar karma in anorectal condition likes piles, fistula in ano, fissure in ano and pilonidal sinus is a better alternative therapy than surgical intervention. Kshar pratisaran can be done in excision of over growth in soft tissues.² these condition includes haemorrhoids, polyps, warts, papillae and also the non healing chronic sinus and ulcers where debridement is an essential factor for healthy healing pattern.³

Patient took treatment from outside hospital but he did not get any relief. When patient visit shalya opd his anorectal examination was done digitally and with proctoscope. On proctoscopy it was found that small 1 degree haemorrhoids were present at 3, 7, 11 o clock. It was explained to the patient and his attendants about the disease and line of treatment i.e. parasurgical (ksharkarma). After required investigation patient patient was posted for kshar pratisaran karma. Patient placed in lithotomy position and proctoscope inserted. With this piles were visualised then kshar applied with cotton wrapped scoop and left for counting upto 100.

CASE STUDY

A male patient 48 years attended the opd of shalya tantra with complaints of bleed per anum during defecation and constipation since 5 month.

***Address for Correspondence:**

Dr. Anju lata,
Lecturer,
Shalya dept. Shri Dhanwantry Ayurvedic College
and Hospital, Chandigarh India.
E mail ID: anjulatabams@gmail.com

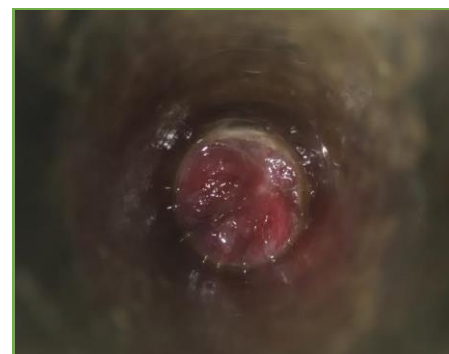


Figure 1: Pre OP

Then kshar was cleaned with lemon juice. Finally after 3 sitting with the gap of 7 days piles mucosa contracted and all symptoms subsides. With this laxatives also given to avoid recurrence.




Figure 2: Intra OP

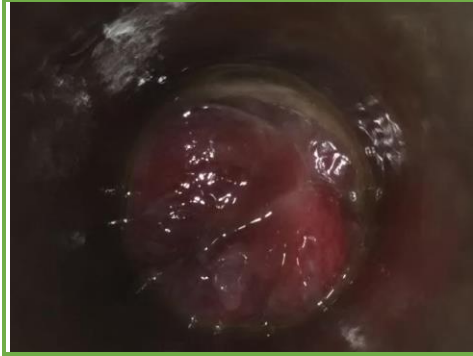


Figure 3: Post OP

DISCUSSION

Kshar pratisaran is found satisfactory in the management of internal pile. Kshar karma not only cure the piles but also minimize its post op complication and recurrence. It is also of low cost and easily affordable to patient.

REFERENCES

1. Ambikadutt, S. (2007). Susruta Samhita edited with Ayurveda tatva sandipika Hindi Commentary. *Chikitsa Sthana 13th chapter, Madhumeha Chikitsa, Chaukhambha Sanskrit Sansthan, Varanasi, reprint edition, 64.*
2. Ambikadutt, S. (2007). Susruta Samhita edited with Ayurveda tatva sandipika Hindi Commentary. *Chikitsa Sthana 11th chapter, Madhumeha Chikitsa, Chaukhambha Sanskrit Sansthan, Varanasi, reprint edition, 87.*
3. Ambikadutt, S. (2007). Susruta Samhita edited with Ayurveda tatva sandipika Hindi Commentary. *Chikitsa Sthana 17th chapter, Madhumeha Chikitsa, Chaukhambha Sanskrit Sansthan, Varanasi, reprint edition, 81.*